14} Placental Examination

Goal:

To ensure accurate assessment of the placenta after delivery in order to identify any abnormalities, confirm placental completeness, and prevent postpartum complications such as hemorrhage or retained placental tissue.

Objectives:

By the end of this procedure, to:

- Prepare the appropriate equipment needed for doing of placenta examination.
- List Functions of the placenta.
- Demonstrate placenta examination
- List congenital abnormalities of the placenta.

Teaching strategies:

1- Lecture discussion and demonstrations presentation highlight soft content is an integral part of the procedure.

2- Practice labs are required. Students practice aspects of the abdominal examination. Faculty members are available for consultation and for evaluation of the student's progress.

3- Simulators doll is generally used to illustrate and demonstrate aspects of physical exam.

4- Clinical experience for this procedure is planned and arranged through various agencies:

Evaluation:

- Clinical exam
- Checklist.

Outlines:

- Introduction
- Definition.
- Functions of the placenta
- Congenital abnormalities of the placenta
- Equipment
- The technique of placenta examination.

Introduction:

The placenta is a remarkable organ. Originating from the trophoblastic layer of the fertilized ovum itself, it links closely with the mother's circulation to carry out functions which the fetus is unable to perform for itself during intrauterine life. The survival of the fetus depends upon its integrity and efficiency. The primitive placenta forms during the 2nd week of pregnancy.Starting from the 12thweek of pregnancy, the young placenta increases rapidly in weight until the 30th week; thereafter, the weight increase is slow until full term.

Definition:-

It means accurate observation & examination of the placenta after its expulsion.

Measuring of the placenta:-

At full term the placenta is an oval or circular cake-like rgan.

- ☞ Diameter: 10: 25.5 cm.
- ☞ Thickness: is 2.5: 3 cm. thick at full term.
- ☞ Weight: 450 : 600 gm

Structures of the placenta:-

1- Maternal surface

It is arises from decidua basalis, in contact with the uterine wall.

It characterized by:-

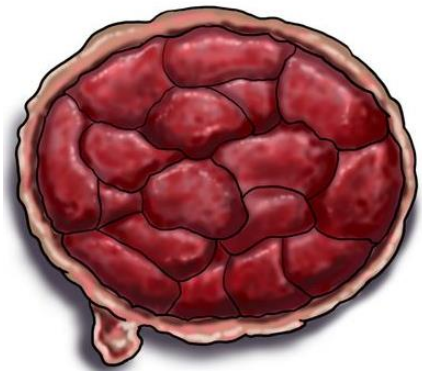

- Dull red in color and divided by grooves into 15—20 lobes called cotyledons and each cotyledon consists of 10 —20 lobules.
- Rough and spongy.
- Partially covered with a thin grey layer of decidua called the basal plate.

2- Fetal surface

Develops from the chrionic villi toward the aminiotic cavity

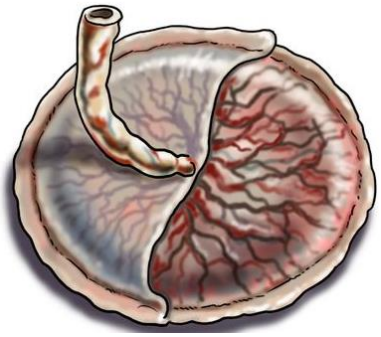

It characterized by:

- Is covered with the aminion which is a thin smooth membrane.
- Grayish in color with permanent blood vessels.

- Contains branches of umbilical veins and arteries.

https://assets.assist.incision.care/organization_data/e25a3698-1d0d-44ff-a48e-1f54f6f346cf/2024-12-19/Placenta-1.jpg

3- Placental barrier

The tissue which separate the maternal from fetal blood are called the placentalmembraneor“barrier”.Intheearlymonthsofpregnancyitisabout 0.025mm.

Functions of the placenta

The placenta performs the following functions:

1- Respiration:-

It oxygenates the fetal blood and removes its carbon dioxide content (it acts as a lung).

2- Nutrition:-

It gives food requirements to the growing fetus (it acts as a gastro- intestinal tract). It also changes complicated food into simpler compounds which are easier to absorb and use by the fetus.

3- Excretion: -

It excretes the metabolic products and noxious material from the fetal circulation (it acts as a kidney).

4- Storage:-

The placenta metabolizes glucose, stores it in the form of glycogen and reconverts it to glucose as required. The placenta can also store iron and the fat-soluble vitamins.

5- Protection:-

The placenta provides a limited barrier to infection. With the exception of treponema of siphilis, viruses and few bacteria can penetrate.

6- Hormonal:-

It secretes large amounts of oestrogens, progesterone, chrionic gonadotrophin and placental lactogen (HPL) (it acts as an endocrine gland).

7- Haemopoietic:-It forms foetal haemoglobin.

8- Enzyme function:-

Various placental enzymes are elaborated such as diamineoxidase, oxytocinase and alkaline phosphatase.

Structure:-

1- The covering epithelium of the amniotic membrane which is adherent and inseparable from the underlying structures.

2- Wharton's jelly:-Which is connective tissue covered by amnion.

3- Blood vessels: - These are three in number:

a) Two umbilical arteries which carry the venous blood from the fetus to the placenta where it is oxygenate

b) The Umbilical vein which carries the oxygenated blood from the placenta back to the fetus.

The length of the cord: - At term the cord is about 50 cm. In length and 2 cm. in diameter. It is usually as thick as the little finger with nods and swelling caused by dilatation of the umbilical vein or formed by simple local increase in Wharton's jelly; these are called false knots.

Insertion of the cord: - The umbilical cord is inserted into the fetal surface of the placenta near its center.

Congenital abnormalities of the placenta

A-Abnormalities of shape and size

Bipartite placenta:-

- ☞ It is made of two equal parts connected together by membranes.
- ☞ There is a single cord which is inserted in one part, or in the membranes between the two parts or it may divide to supply

each part.

https://www.google.com/search?q=+bibartite+placenta&client=firefox-be&sca_esv=53a7f9f69fe1adbf&udm=2&biw=1366&bih=643&ei=mqWAaOn9E57Xi.

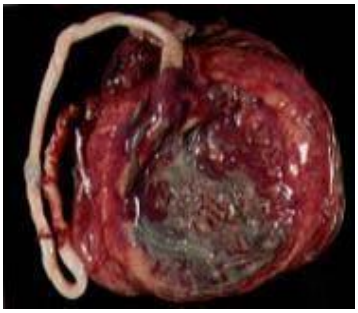

Placenta succenturiata:-

☞ The placenta is made of two unequal parts connected by membranes. The cord is inserted in the big part and branches of the umbilical vessels pass through the membranes to reach the small accessory lobe. The dangers of this accessory lobe are:

- ✓ It may retain in the uterus without being noticed.
- ✓ It may have a low insertion forming placenta praevia.

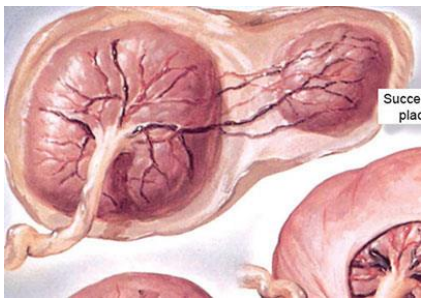

- ✓ One of its feeding vessels may cross the membranes over the internal os and may cause severe bleeding when the membranes rupture during labor.

https://d45jl3w9libvn.cloudfront.net/jaypee/static/books/9788184485523/Chapters/images/113-1.jpg

Circumvallate placenta:-

There is a white ring of decidua around the edge of the placenta

on its fetal surface. It is about 1 cm. In width. It may lead to abortion, preterm labor, intrauterine growth retardation and slight increase of congenital malformation.

https://www.google.com/search?client=firefoxe&sca_esv=53a7f9f69fe1adbf&q=Circumvallate+placenta:&udm=2&fbs=AIIjpHwHiZMzyjcx1TS4wIfAvBUtBHTKorh1bOdzCGcLIX.

Membranousplacenta:-

Agreatpartofthechoriondevelopsintoplacentaltissue.Theplacentaislarge and thin and may measure 15 — 20 inches in diameter.

B-Abnormal adhesion of the placenta

The decidua basalis is absent or poorly developed and so the chorionic villi penetrate deeplyinto the uterine wall. When the villi come just in contact with the muscle layer it is called placenta accreta. When the villi penetrate into the muscle layer it is placenta increta and when they reach the peritoneal coat it is placental percreta.

C-Abnormal weight

Normally, the placenta at term is about one-sixth of fetal weight. In congenital syphilis, diabetes mellitus and hydrops fetalis the size and weight of placenta increases to be 1/3 or *1/2* of fetal weight.

D-Abnormal Position

1- **Placenta praevia:-**As a result of low implanation of the ovum, the placenta develops near to or covers the internal os.
2- **Corneal placenta: -** When the placenta is situated at one cornua of the uterine cavity.
3- **Fundal placenta:-** When the placenta occupies the fundus of the uterus.

➔ **(Normal umbilical cord)** The umbilical cord extends from the fetus to the placenta; it connects the fetus with the placenta and carries blood to and from the placenta.

E-Abnormalities in umbilical cord

1) Abnormalities in insertion of the cord:

A) **Battledore placenta:** The cord is inserted in the margin of the placenta instead of its middle.

B) **Velamentous placenta: -** The cord is inserted in the membranes outside the placenta margin. The umbilical vessels pass through the membranes to reach the placenta.

https://www.google.com/search?client=firefox-b-e&sca_esv=53a7f9f69fe1adbf&q=B)+Velamentous+placenta&udm=2&fbs.

2) Abnormalities of the umbilical cord

1- **Short cord: -** Cord32cm. Or less. The cord may be absolutely short, or relatively short due to looping of the cord around the fetus.

2- **Long cord:-**Lengthis100cm.ormore.

3- **Knotes of the cord:-**True knot; formed when the fetus passes through

a loop of the cord. When tight it causes fetal asphyxia and even death.

Single umbilical artery: - It leads to congenital fetal malformation in about 50% in cases.

https://embryology.ch/en/media/module10/noeud01.jpg

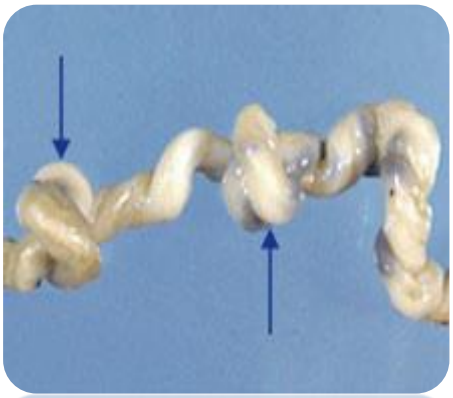

Cut section of the cord, true and false knots

https://content.app-sources.com/s/5177295118943168/uploads/Blog/Blog_two-vessel-umbilical-cord-what-does-that-mean_Cover-6060695.jpg

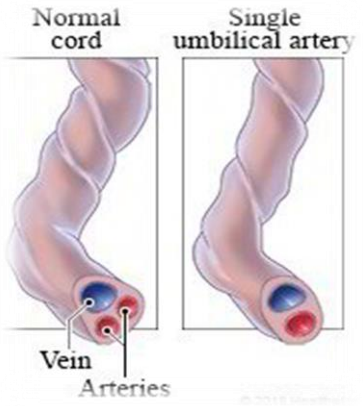

Clinical examination of the placenta

Indications:-

At deliveryitisusefulforthecliniciantoexaminetheplacentainsomedetailand record the findings. The examination of the placenta is particularly important in some cases:

1- Placentas, from all stillbirths.

2- Placentas from all mothers with significant Antepartum disease such as hypertension and D.M.

3- Placentas from all grossly abnormal fetuses.

4- All grossly abnormal placentas.

5- All twin placentas.

6- Placentas from pregnancies resulting in preterm birth.

7- Placentas from pregnancies in which mother or infant appear to be infected.

8- Placentas from pregnancies resulting in the delivery of ill newborn.

9- Placentas from pregnancies resulting in infants those are small or large.

The equipment:-

- Gloves and apron
- Disposable protective cover
- Disposable bag for placenta.
- Placenta.
- Round basin or large iodine bowl.

Examination of the placenta:

Nursing action	Rational
1-Gatherequipment.	
2-Washhandsandapplyglovesandapron.	-To prevent spread of micro organisms
3- Receive the placenta in a round basin and wash it carefully under running water.	- To examine it. - To remove any blood clots. - To have made accurate view.
4- Carry the placenta in your cupped hand or place the placenta on a flat surface.	-To observe it carefully. -To observe all the placental lobes or cotyledons
5-Lay the placenta, fetal surface upper most, onto the cover (placed on a flat surface).	-To facilitate good observation.
6-Notethesize, odor and color of the fetal surface.	-Large size is indication of fet -A pale placenta may reflect delay

	Clamping of the cord, it could also indicate intrauterine anemia -An offensive smelling is often indicative of intrauterine infection.
7-Examine the cord, noting the length, insertion point and presence of knots.	-To detect any deviation from the norm. -To treat any deviation from the norm. -To prevent complication. -Normally the cord should be free from any knots.
8- Count the number of vessels in the cut end of the cord (if the end has been obliterated, cut off a small portion of the cord and count the vessels in the portion remaining.	- A cord with fewer than three vessels may indicate a congenital abnormality; the baby should be referred to the pediatrician and a sample of the cord may be required for analysis.
9-Observe the fetal surface for irregularity.	

10-Taking hold of the cord with the non- dominant hand, lift the placenta from the surface and examine the hole in the membranes and replace on surface.	- If the membranes appeared ragged, apiece of membrane may be retained in uterus. This can affect uterine contractility and predispose to p.p.h.
11-Spread the membranes outward, looking for extra vessel or lobes, or unexplained hole.	
12-Turntheplacentaover, maternal side uppermost.	
13- Examine the cotyledons, ensuring all are present, noting the size and amount of areas	-the presence of red or whitish nodules that
Of infarction or blood clots.	May represent tumors, infarcts or intervillous thrombi.
14-Observeplacentalsize& shape.	-
15-Weightorswabtheplacentaif indicated.	
16-Disposeoftheplacentaandequipment correctly.	
17-Washhandsproperly.	-To avoid contamination and/or cross infection.

14-Recordingandreporting:- ☞ Date of delivery. ☞ Time of placental expulsion. ☞ Time of placental examination. ☞ Types of abnormality. ☞ Reporting any deviation from normal.	

Placental Examination Checklist

First Trial Done	Second Trial		First Trial	
	Note Done	Done	Note Done	Done
1. Procedure steps				
2. Gather equipment.				
3. Wash hands and apply gloves and apron.				
4. Receive the placenta and wash under running water.				
5. Lay the placenta, fetal surface upper most on a flat surface.				
6. Note the size, odor and color of the fetal surface.				
7. Observe the insertion of the cord.				
8. Check the length of the cord.				
9. Count the number of vessels in the cut end of the cord.				
10. Check presence of knots.				
11. Observe the fetal surface for irregularity.				
12. Taking hold of the cord with the non-dominant hand, lift the placenta from the surface and examine the hole in the membranes and replace on surface.				

13. Spread the membranes outward, looking for extra vessel or lobes, or unexplained hole.				
14. Turn the placenta over, maternal side uppermost. Examine the cotyledons, ensuring all are present, noting the size and amount of areas of infarction or blood clots.				
15. Weight or swab the placenta if indicated.				
16. Dispose of the placenta and equipment correctly.				
17. Record& report.				
Score:				
Date				

Student name: Instructor name: